

Paleopathology of Skeletal Fluorosis

JUDITH LITTLETON*
*Department of Anthropology, University of Auckland,
Auckland, New Zealand*

KEY WORDS fluoride; prehistoric Arabia; Bahrain; endemic fluorosis

ABSTRACT Skeletal fluorosis is one of a range of conditions causing excessive ossification and joint ankylosis in skeletons. It is rarely considered, however, in differential diagnoses of palaeopathological lesions. This paper considers the identification of skeletal fluorosis in a skeletal sample from the island of Bahrain, Arabian Gulf, dating to ca. 250 BC–AD 250.

Approximately 4% of 255 adult skeletons in the sample have hyperostotic lesions resulting in joint ankylosis primarily of the lumbar vertebrae, as well as the major joints. These lesions most frequently occur among males in the 50+ age group. Chemical analysis on a small series of bone and dental samples confirmed the presence of high levels of fluoride, while staining of the teeth is evidence of dental fluorosis. The level of dental fluorosis is comparable with a naturally occurring fluoride level in water of between 1–2 ppm. The prevalence of hyperostotic lesions, however, appears higher than expected, and two possible reasons are suggested: confusion between a diagnosis of diffuse idiopathic skeletal hyperostosis and skeletal fluorosis on partial or less severely affected skeletons; and the presence of predisposing factors for skeletal fluorosis on the island in the past. *Am J Phys Anthropol* 109:465–483, 1999. © 1999 Wiley-Liss, Inc.

Palaeopathological studies have frequently demonstrated the difficulty of diagnosing the cause of skeletal lesions, particularly between hyperostotic conditions (Rogers et al., 1987; Crubezy, 1990). Endemic fluorosis due to naturally occurring high levels of fluoride in water and soil is a major health problem in some parts of the world today (Teotia and Teotia, 1984). While modern cases of the disease include those due to industrial intoxication, airborne fluorides in coal, and deep well bores (Mwainiki et al., 1994; Wang and Huang, 1995), there is no reason to assume it was not also a problem in the past. Recent analyses from North India (Lukacs et al., 1985) and Pompeii (Torino et al., 1995) have pointed to the presence of high fluoride levels in some ancient populations, including ancient China (Wang and Huang, 1995).

While fluorosis is rarely considered as a possible cause of pathological changes in skeletal samples, in areas with naturally high fluoride levels it obviously needs to be taken into account. The aim of this paper was, through examination of a skeletal population from Bahrain, to clarify the identification of skeletal fluorosis, which is often ignored as a probable cause of hyperostotic lesions in skeletal remains.

BACKGROUND: SKELETAL FLUOROSIS

Skeletal fluorosis results from the ingestion of excessive amounts of fluoride. There is no fixed toxic level of fluoride, since the

Grant sponsor: Ministry of Information, Bahrain; Grant sponsor: ANU Australian Postgraduate Research Award scholarship.

*Correspondence to: Judith Littleton, Department of Anthropology, University of Auckland, Private Mail Bag 92019, Auckland, New Zealand. E-mail: J.Littleton@auckland.ac.nz

Received 18 September 1995; accepted 1 April 1999.

development of fluorosis depends upon environmental factors. Intoxication can result from acute doses, but more commonly the condition is chronic due to prolonged intake of high levels of fluoride (above 0.7 ppm in some places; Jolly et al., 1973). The most common natural source of fluoride in these cases is water, especially well and spring water where the surrounding substrata contain fluoride (Teotia and Teotia, 1988).

When excessive amounts of fluoride are ingested, a series of biochemical changes occurs (Mariano-Menez et al., 1990). Fluoride is rapidly absorbed into serum through the stomach and upper intestine. The absorbed fluoride is carried to the bone, where it can replace hydroxyl in the bone hydroxyapatite, creating fluoroapatite. This occurs most rapidly in the trabecular portion of the bone (Teotia and Teotia, 1988). The abnormal bone has an increased density. The absorbed fluoride also stimulates the formation of new irregular bone at the sites of tendon and ligament insertions, resulting in gradual ossification of soft tissues. In the presence of adequate dietary calcium, the main picture is of osteosclerosis; however, in cases where dietary calcium is inadequate, the absorbed fluoride may result in secondary hyperparathyroidism, leading to bone loss, so that bone density may include areas of both sclerosis and porosis (Teotia and Teotia, 1988; Mithal et al., 1993). This osteoporotic type of skeletal fluorosis occurs in children and younger adults, particularly in areas with extremely high levels of fluoride in the water (Christie, 1980; Krishnamachari, 1986).

While airborne exposure through coal fires and dust has been reported (Haikel et al., 1986; Wang and Huang, 1995), most commonly the osteosclerotic type of fluorosis only develops after 15–20 years of continuous exposure to water containing high levels of fluoride (Jolly et al., 1969). The minimum water level ever reported as causing changes is 0.7 ppm (Jolly et al., 1973), but there is no clear linear relationship between the amount of fluoride in drinking water and the development of skeletal fluorosis (Chibole, 1987). Studies in temperate, developed countries have demonstrated no significant signs of skeletal fluorosis in communities with water

levels of 4 ppm (McClure et al., 1958; Kaminsky et al., 1990), yet work in some Indian villages has demonstrated skeletal fluorosis when the water level is much lower (Moudgil et al., 1986; Teotia and Teotia, 1988). Influencing factors other than water level appear to be period of exposure, climate, other trace elements in the water, dietary intake of fluoride, nutritional status, water storage methods, work patterns, and tea-drinking habits (Jolly et al., 1969; Haikel et al., 1986; Zietsman, 1991).

The major signs of fluorosis are in the dentition and the skeleton. Teeth are affected by fluorotic staining and pitting of the surface enamel (Moller, 1982). Fluorosis in the skeleton is marked by increased bone production, and thickening and coarsening of bone trabeculae, with a corresponding increase in bone density resulting in a "ground glass" appearance on X-rays (Bullough and Vigorta, 1984; Wang et al., 1994). The entire skeleton is affected. The cranium becomes thick and heavy with gradual obliteration of the diploe, while ossification of ligaments results in the development of irregular margins around the foramen magnum. Postcranial bones become heavy and irregular, with abnormal prominence of muscle and tendinous insertions and visible enthesophytes (Rogers and Waldron, 1995). Ossification of spinal ligaments is common, especially of the ligamenta flava, and intra-transverse and interspinous ligaments. In severe cases, compression of the spinal cord can result (Misra et al., 1988). The vertebral bodies appear larger than normal, and eventually there is complete fusion of the vertebrae by thick osteophytes. These changes are most common in the cervical and lumbar regions. The ribs appear large and have roughened surfaces due to ligament ossification. Ankylosis of the costovertebral and costosternal joints may occur, with consequent "freezing" of the chest cavity in an aspirated position (Jolly et al., 1969). Calcification of ligamentous and tendinous insertions is most marked on those areas of the skeleton subject to strain, especially the linea aspera, the interosseous membrane between the radius and ulna and the tibia and fibula, and the sacrotuberous and sacrospinous ligaments (Moller and Gudjonsson,

1967). In advanced cases, ankylosis may occur in these locations (Teotia and Teotia, 1988). The disease tends to affect older adults, and men more frequently than women (Jolly et al., 1969).

The condition has been regularly reported in certain regions of the world where fluoride occurs at naturally high levels. These include North India (Teotia and Teotia, 1988), parts of Africa (Chibole, 1987; Mwainiki et al., 1994), parts of China (Wang et al., 1995), and the Arabian Gulf (the origin of the current sample; FitzGerald-Finch, 1981).

In 1983, a single probable case of skeletal fluorosis was found among Bronze Age human remains from Bahrain Island (Frohlich et al., 1989). Changes characteristic of skeletal fluorosis were identified, and the diagnosis was confirmed by chemical analysis of the bone, revealing a 1% fluoride level. At the time, it was assumed that this was an unusual case and that this individual had been a foreigner to Bahrain, possibly from North India (Frohlich et al., 1989).

Since then, however, both dental and skeletal changes reminiscent of fluorosis have been found in other skeletal samples from the island (e.g., Littleton and Frohlich, 1989). In particular, during a more extensive survey of paleopathological patterns among skeletons from a Hellenistic cemetery on the island, many individuals with ossification at the ligament and tendinous insertions and osteophytic growth around the joint margins were recorded (Littleton, 1993).

While there are several possible causes of such ossification, this paper illustrates the importance of considering fluorosis. It argues that many of the changes observed in the Bahrain population are indicative of skeletal fluorosis. The prevalence of the disease is explained by considering predisposing factors for fluorosis, and the possible social impact of the disease is assessed.

THE AREA AND THE SAMPLE

The state of Bahrain is located halfway along the Arabian Gulf, 30 km from the eastern shore of Saudi Arabia (Fig. 1). It is a small group of islands, the main one (Bahrain Island) being approximately 30 km wide and 50 km long. Traditionally, the islands' inhabitants relied upon a mixture of agricul-

ture, fishing, and trading. Sweet water is derived from a fluctuating supply from natural aquifers which arise in Saudi Arabia (Larsen, 1983). The aquifer was tapped on the island by a series of wells extending down into the underground basin, as well as a small number of natural springs. Water levels have fluctuated over time and settlement on the island has been dependent upon this, contracting towards the north and west of the island when water levels decline. The island receives less than 7 cm of rainfall a year and therefore agriculture was totally dependent upon this underground water supply prior to the development of desalination.

The island is known to have been occupied from 7000 BP to the present. The skeletal sample described in this current work dates from the Hellenistic or Tylos period, ca. 2300–1700 BP, which appears to have been a time of relative prosperity and active trading in manufactured goods, in addition to staples such as dates, wood, and grain (Salles, 1987).

The human remains come from the DS3 cemetery, which is part of the al-Malikiyah mound field. This area contained a mixture of Iron Age and Hellenistic tombs and lies on the western edge of a Bronze Age mound-field. The site was completely excavated by the Bahrain Directorate of Archaeology and Museums between 1984–1986 except for approximately 20% of the cemetery, bulldozed prior to excavation. The remaining area comprised a minimum of 15 burial mounds. The absolute number of graves is 292, of which 38 contained no skeletal material.

The burial ground was located on non-arable land bordering irrigated land. Aerial survey suggests that a settlement site was located nearby and that the cemetery probably derived from the inhabitants of a small village in the immediate area (Littleton, 1998). Based on population size estimates from the cemetery, the village would have contained, on average, between 100–250 individuals. Dietary reconstruction on the basis of archaeological as well as dental and skeletal evidence suggests that the people buried in the cemetery followed an agricultural lifestyle, possibly supplemented by fishing. The maintenance of the cemetery

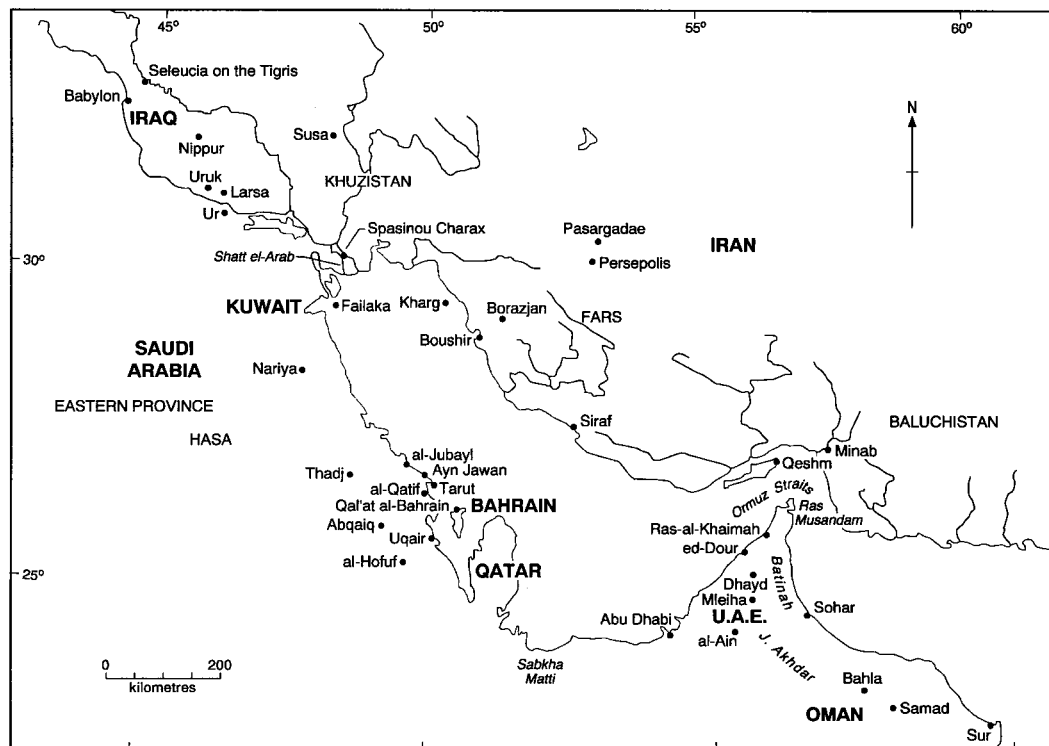


Fig. 1. Location of Bahrain in the Arabian Gulf.

over time and relative lack of expenditure on these graves suggest that the area was used by local residents (Littleton, 1998).

The total number of individuals from the DS3 cemetery was 1,051. Of these, 631 were subadults. Many of the skeletons, however, were incomplete. Paleopathological data are therefore analyzed on two levels: individuals for whom age and sex could be assigned, and the total number of individual skeletal elements. The sample composition can be seen in Table 1. When left- and right-side bones were present in one individual, right-side bones were recorded. In general, however, there was little discordance between sides in severity of lesions.

METHODS

Age and sex were designated through the use of multiple indicators. Morphological features of the pelvis and crania were used for the identification of sex (Phenice, 1969; Brothwell, 1981). Where possible, adult ages were assigned to 10-year age groups (50+

was the oldest group). A combination of pubic symphysis changes (Meindl et al., 1985), sacroauricular surface indicators (Lovejoy et al., 1985), degree of epiphyseal closure (Bass, 1981), and cranial suture closure (Meindl and Lovejoy, 1985) were used for adult age estimation.

Pathological conditions were recorded in several categories, none of which, strictly speaking, were mutually exclusive. These were: traumatic, resorptive (porotic hyperostosis, osteoporosis), proliferative (e.g., periostitis, osteomyelitis), or sclerosing/hypertrophic (Powell, 1988; Littleton, 1993). Initially it was expected that this final condition would include neoplasms. In the entire sample, however, only two cases of probable benign osteomata were found. Instead it was observed that a large number of bones showed signs of excessive ossification of the ligaments and interosseous membranes, accompanied by some disorganization of the bone cortex. As a result, each bone was graded into one of four categories: 0, normal;

TABLE 1. Sample composition by skeletal element¹

| Element | Male | Female | 20–29 yr | 30–39 yr | 40–49 yr | 50+ yr | Total |
|-------------------------|------|--------|----------|----------|----------|--------|-------|
| Occipital | 67 | 57 | 27 | 28 | 1 | 36 | 125 |
| Parietal | 150 | 156 | 55 | 66 | 38 | 16 | 312 |
| Orbit | 105 | 116 | 51 | 41 | 26 | 18 | 122 |
| Frontal | 63 | 63 | 23 | 29 | 19 | 9 | 126 |
| Face | 24 | 20 | 9 | 7 | 4 | 5 | 44 |
| Basicranium | 26 | 29 | 13 | 9 | 6 | 4 | 55 |
| Endocranium | 29 | 44 | 18 | 15 | 7 | 5 | 73 |
| Temporal | 115 | 126 | 49 | 50 | 28 | 16 | 251 |
| Mandible | 29 | 34 | 12 | 15 | 10 | 7 | 61 |
| Cervical vertebrae | 60 | 57 | 28 | 31 | 18 | 13 | 119 |
| Thoracic vertebrae | 67 | 63 | 30 | 34 | 17 | 14 | 132 |
| Lumbar vertebrae | 68 | 60 | 30 | 36 | 17 | 14 | 130 |
| Sacrum | 48 | 38 | 20 | 21 | 15 | 13 | 87 |
| Pelvis | 127 | 109 | 55 | 76 | 32 | 33 | 236 |
| Ribs | 47 | 42 | 21 | 18 | 15 | 11 | 90 |
| Sternum | 28 | 24 | 13 | 9 | 10 | 7 | 55 |
| Clavicle | 111 | 119 | 61 | 57 | 29 | 22 | 235 |
| Scapula | 79 | 66 | 34 | 32 | 18 | 23 | 145 |
| Humerus | 134 | 111 | 54 | 54 | 26 | 28 | 146 |
| Radius | 123 | 104 | 48 | 60 | 24 | 24 | 229 |
| Ulna | 111 | 94 | 41 | 48 | 24 | 24 | 205 |
| Hand | 25 | 22 | 10 | 9 | 7 | 4 | 47 |
| Femur | 139 | 116 | 56 | 63 | 26 | 27 | 255 |
| Patella | 75 | 61 | 41 | 30 | 20 | 8 | 69 |
| Tibia | 104 | 89 | 40 | 30 | 17 | 19 | 193 |
| Fibula | 85 | 79 | 38 | 43 | 20 | 18 | 165 |
| Foot | 74 | 65 | 34 | 35 | 18 | 22 | 142 |
| Dentitions ² | 74 | 78 | 21 | 19 | | | 165 |

¹ Right side; left used only when right side not present.

² Two or more teeth present.

1, slight—accentuation of muscle markings, increased robusticity of the bone (Fig. 2); 2, moderate—ossification of ligamentous insertions and interosseous membranes (3–10 mm), with protruding masses of bone, and the beginning of joint ankylosis (Fig. 3); and 3, ankylosis of joints, near complete ligament ossification (Fig. 4).

Some of these increases in rugosity may have been due to physical activity and age (Crubezy, 1990) and not due to a pathological condition. In subsequent analysis, therefore, only moderate-severe cases were considered (i.e., enthesophytes >3 mm in length or ankylosis).

Both each bone and each individual skeleton were scored according to this scale. Individual skeletons were classified into unaffected, slight, moderate, or severe classes on the basis of condition of the majority of the bones.

All permanent teeth were also recorded, using a recording scheme adapted from Dean (1934) and Jolly (Jolly et al., 1969). Four categories were identified: 1, normal—translucent enamel, no sign of brownish staining;

2, slight—scattered white opacities on the tooth's surface; 3, moderate—superficial and minute pitting, brownish staining; and 4, severe—marked pitting with widespread staining.

Postmortem staining of teeth in burial deposits is common. In this instance, stains were only recorded when it was obvious that the mark was formed within the enamel and was resistant to removal by acetone; in addition, the determination of fluorosis was dependent upon the observation of opacities and pitting (Thylstrup and Fejerskov, 1978). Individuals were categorized as having mild, moderate, or severe changes on the basis of the two most severely affected teeth in their dentition.

Chemical analysis of four teeth and bone fragments from three individuals was conducted. Dental analysis by electron microprobe scanning was conducted by Dr. G. Suckling of the Dental Research Unit, Medical Research Council of New Zealand. Following established methodology, scans were taken through each tooth to determine changes in fluoride level due to diagenesis



Fig. 2. Slight ossification along linea aspera on distal (top) and proximal (middle) and femur moderate changes to patella.

(Suckling et al., 1992). The human bone was tested by atomic absorption spectrometry at the Department of Chemistry, Australian National University, following the methodology described by Szpunar et al. (1978). Since fluoride is subject to diagenesis and accumulates in bone over time, samples were taken from the surface and from the middle of the bone cortex. Soil samples from the graves were also tested to determine whether the soil content in Bahrain contained high levels of fluoride which could affect buried remains.

RESULTS

Skeletal material

Table 2 demonstrates the distribution of all lesions throughout the adult skeletons from DS3. No subadult bones were found to have any evidence of skeletal hypertrophy. However, adult skeletal elements with extensive muscular attachments frequently showed signs of excessive ossification. Thus the skull tended to be affected very little

with the exception of the basicranial area, the area of the nuchal line and mastoid, and the gonial angle of the mandibular ramus. A small proportion of these bones (<5%) showed signs of overdevelopment of the muscle attachments (stage 1); none, however, showed more definite evidence of ligament ossification.

The postcrania in the sample were more frequently affected. Major effects were seen in the thoracic area (24.7% of ribs and 11.0% of thoracic vertebrae, including all stages). Fusion, or near fusion, of the sternocostal joints occurred, with progressive ossification of the anterior ligaments covering the sternal body.

In the sample, the probability of bone ankylosis and ligamentous ossification was greatest in the lower vertebrae, with the lumbo-sacral area being most frequently affected. This ankylosis can be readily distinguished from osteophytosis, since the first ligaments to show signs of ossification were




Fig. 3. Moderate enthesophytes on patella (right) compared to normal (left).

the supra- and interspinous ligaments along the neural arch (Fig. 4) (Rogers and Waldron, 1995). Osteophytic growth on the vertebral bodies tended to be flowing ossification from the central body, rather than horizontal outgrowth (Fig. 4). There were no accompanying signs of joint degeneration such as porosity or eburnation of the articular surfaces.

Figure 5 is an X-ray of a severely affected spine (from T8 to L4) compared to a normal vertebral column from DS3. While the pathological spine was damaged postmortem, several characteristic features of this pathological condition are demonstrated. The anterior spinal ligaments are fused, and thick osteophytes protrude from the central anterior vertebral body. Complete ankylosis has occurred on several vertebral bodies, especially L2–L4, with encroachment upon the intervertebral disc space; all intervertebral disc spaces show signs of marked narrowing. The posterior spine on T8 has a roughened surface with exostoses along the lower border, and the apophyseal joints, where visible, are surrounded by osteophytes. The most obvious difference between the two spines, however, is the degree of radioden-

sity. The pathological case is near opaque with markedly greater density of bone, indicative of osteosclerosis.

In the sample, the pelvis was also frequently affected, even more commonly than the sacrum. The major ligament insertions, particularly the sacro-tuberous ligament, were visibly ossified in 5.1% of pelvis. In severe cases, joint ankylosis occurred, primarily at the sacroauricular joint.

In comparison to the trunk the limbs were less affected, and arms less than legs. The clavicles and scapulae only rarely showed any definite signs of joint ankylosis, though an increased degree of muscle marking was observable. Signs on the humerus, radius, and ulna were more frequent and obvious. Changes to the humeri included increased development of the deltoid tuberosity, gradual ossification of the ligaments at the sites of insertion, and ossification of the muscle attachments around the olecranon fossa.

Ossification of the ligament insertions on the radii and ulnae was generally apparent, particularly on the olecranon of the ulna and around the radial tuberosity. Ossification of the interosseus membrane was also ob-

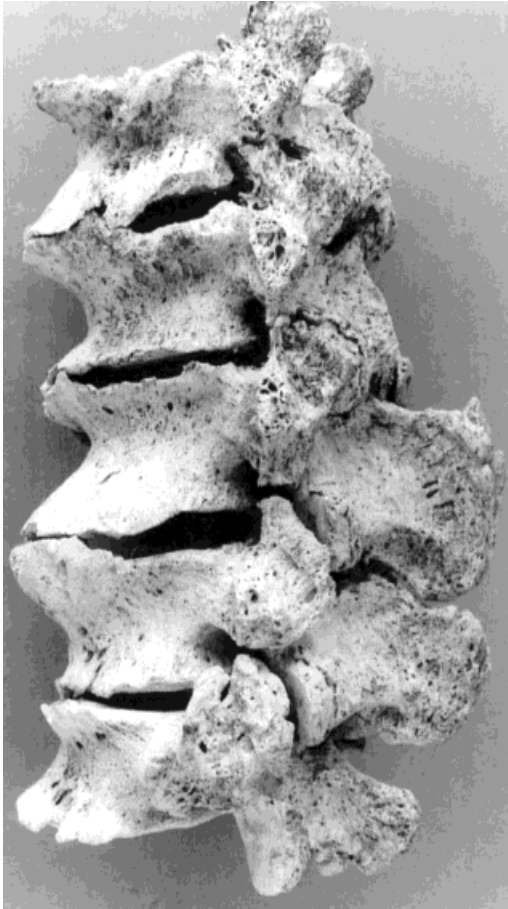


Fig. 4. Severe osteophytosis (joint ankylosis) of lumbar vertebrae (L1-5). Breaks between L1-L2, and L3-L4 post-mortem. Note ankylosis of vertebral arch between L1-L3.

served, although complete fusion of the two bones was not found. In contrast, the bones of the hand had no visible enthesophytes.

After the changes to the vertebrae and ribs, the most characteristic changes were seen in the bones of the leg. The foot was most frequently and severely affected, with 7.7% of feet showing evidence of excess ossification, particularly of the talo-calcaneal ligament (Fig. 6). Changes to the femur were generally nonspecific, consisting of increased rugosity in the attachment of the linea aspera and the insertion of the patellar ligament; only 1.2% had measurable enthesophytes. Changes in the patella included the gradual ossification of the anterior patellar ligament so that, in severe cases, spic-

TABLE 2. Prevalence of moderate-severe enthesophytes among Bahrain adults (%)

| Element | All adults | | 30-40 years old | | | 40-50 years old | | 50+ years old |
|----------------|------------|---------|-----------------|------|------|-----------------|------|---------------|
| | Males | Females | | | | | | |
| Cervical vert. | 0.0 | 0.0 | 0.0 | 0.0 | 0.0 | 0.0 | 0.0 | |
| Thoracic vert. | 1.5 | 3.0 | 0.0 | 0.0 | 0.0 | 0.0 | 14.3 | |
| Lumbar vert. | 2.3 | 4.4 | 0.0 | 0.0 | 0.0 | 0.0 | 21.4 | |
| Sacrum | 3.4 | 6.3 | 0.0 | 0.0 | 0.0 | 0.0 | 15.4 | |
| Pelvis | 5.1 | 7.6 | 3.7 | 1.3 | 9.4 | 12.1 | | |
| Ribs | 6.7 | 10.6 | 2.4 | 5.6 | 6.7 | 27.3 | | |
| Sternum | 12.7 | 21.4 | 4.2 | 11.1 | 0.0 | 57.1 | | |
| Clavicle | 0.4 | 1.8 | 0.0 | 0.0 | 3.4 | 0.0 | | |
| Scapula | 1.4 | 0.5 | 0.0 | 0.0 | 5.6 | 4.3 | | |
| Humerus | 4.1 | 6.0 | 0.0 | 3.7 | 0.0 | 14.3 | | |
| Radius | 2.2 | 6.6 | 0.0 | 0.0 | 0.0 | 16.7 | | |
| Ulna | 3.9 | 7.4 | 0.0 | 4.2 | 0.0 | 25.0 | | |
| Hand | 0.0 | 0.0 | 0.0 | 0.0 | 0.0 | 0.0 | | |
| Femur | 1.2 | 3.0 | 0.0 | 0.0 | 0.0 | 7.4 | | |
| Patella | 2.9 | 2.9 | 0.0 | 0.0 | 0.0 | 12.5 | | |
| Tibia | 2.6 | 4.0 | 0.0 | 0.0 | 0.0 | 15.8 | | |
| Fibula | 3.6 | 6.5 | 2.0 | 2.3 | 0.0 | 16.7 | | |
| Foot | 7.7 | 9.8 | 3.7 | 0.0 | 0.0 | 22.7 | | |
| Individuals | 7.1 | 21.6 | 11.5 | 10.0 | 23.8 | 15.8 | | |

ules of bone protruded vertically from the anterior surface in both inferior and superior directions.

As with the radius and ulna, the tibia and fibula showed ossification of the interosseus ligaments, marked ossification of the patellar ligament insertion, and ossification of the interosseus membrane. In moderate-severe cases, spicules of bone protruded from each of these locations, resulting in one individual with ankylosis of the tibia and fibula.

Female skeletons were much less frequently affected by these changes (Table 2; 16.7% compared to 37.3% considering all stages; $P < 0.001$), although the pattern of changes throughout the skeleton was similar (Spearman's rank correlation $r = 0.597$; $P = ns$). Among males, moderate-severe changes were observed in most types of skeletal elements. Among females only the pelvis, ribs, sternum, fibula, and foot showed signs of moderate-severe changes, although the numbers were too small to test this difference statistically. This lower frequency occurred despite the fact that the pelvic area in females is subject to marked trauma and possible ligament ossification due to childbirth (Angel, 1971).

This condition is age-related (Table 2). No bones in the 20-30-year age group were affected. In the 30-40-year age group, only

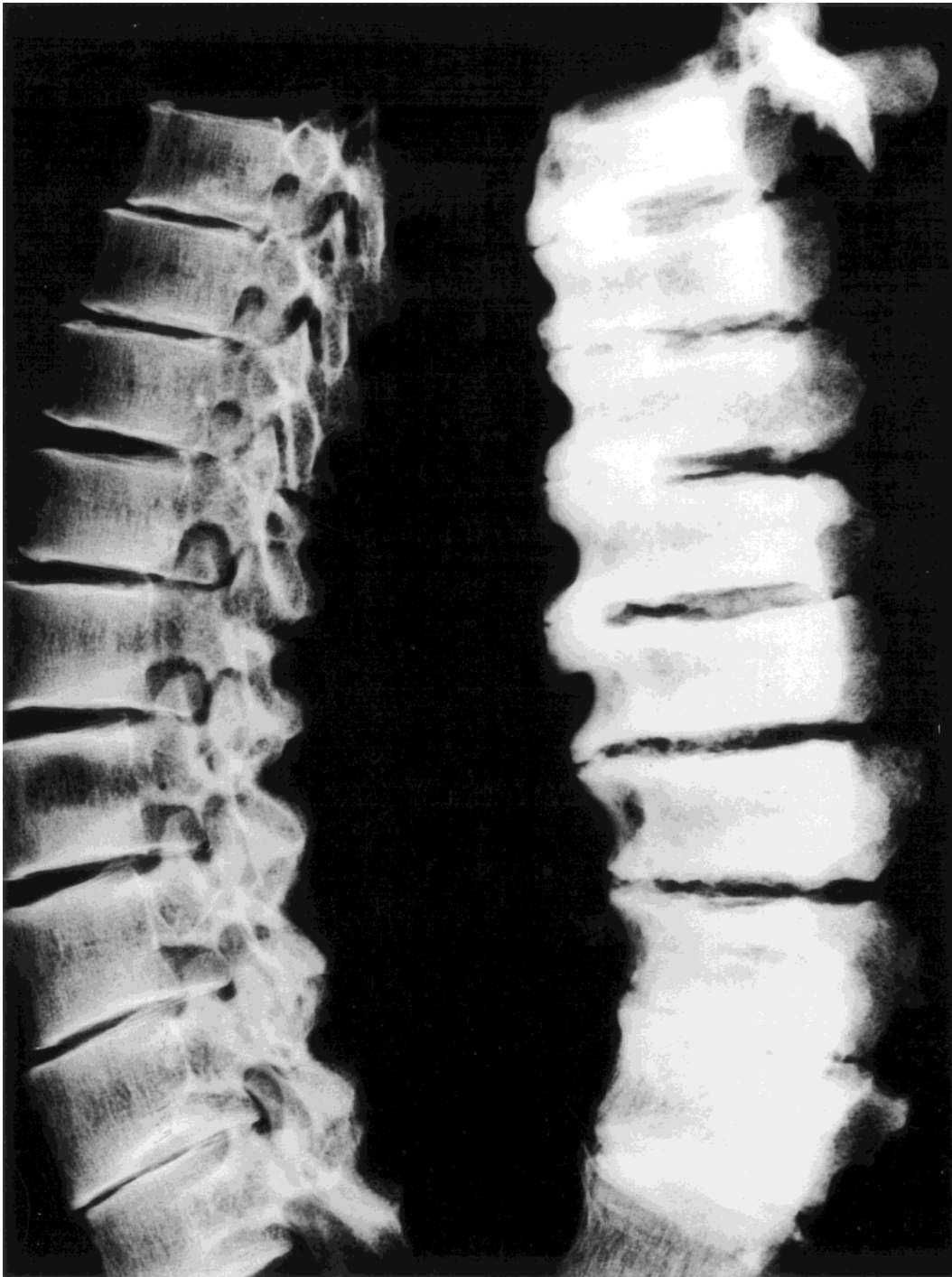


Fig. 5. X-ray of affected spine (right) compared to normal spine from DS3 (left).




Fig. 6. Ossification of the talo-calcaneal ligament particularly marked on calcaneus (right).

the pelvis, ribs, sternum, humerus, ulna, and fibula had any evidence of moderate-severe changes. In the 40–50-year age group, the percentage of affected bone increased, but only a small number of elements were affected. A marked increase was observed in the 50+ age group. Cases of extensive joint ankylosis were only observed in this oldest age group.

Sample sizes were too small to analyze the relationship of moderate-severe changes with both age and sex. Very few females belonged to the oldest age group, and very few females were affected overall.

In its severe form, the condition appears to have been a disease of the oldest members of the society, though there was obviously a progression in both prevalence and severity during adulthood. Female skeletons tend to be less frequently affected and certainly less severely than males. The pathological changes suggest a chronic and steadily developing disease, eventually affecting the majority of the population.

Teeth

Due to widespread antemortem tooth loss in the Bahrain populations, particularly in

TABLE 3. Prevalence of dental fluorosis among adult dentitions

| | N | Fluorotic (%) | Moderate-severe (%) | Severe (%) |
|-----------------|-----|---------------|---------------------|------------|
| 15–20 years old | 10 | 30.0 | 10.0 | 0.0 |
| 20–30 years old | 21 | 47.6 | 23.8 | 9.5 |
| 30–40 years old | 19 | 21.1 | 15.8 | 0.0 |
| All adults | 165 | 44.8 | 18.2 | 4.9 |
| Males | 74 | 48.6 | 21.6 | 4.1 |
| Females | 78 | 46.2 | 11.5 | 6.4 |

the oldest age groups (Littleton and Frohlich, 1989), fluorotic staining on the teeth could not be definitely associated with postcranial changes in any one individual. Among the entire sample of adults from DS3, 44.8% had some degree of dental fluorosis (Table 3). Most of these changes were mild, although 5% of the population had severe changes in the form of marked pitting and widespread staining.

Chemical analysis

Samples of bone were analyzed from three individuals. Samples were selected from fragmentary remains, using the midshaft of the femur. Of the three individuals selected, only one (S5/38) had any evidence of osteo-

TABLE 4. Fluoride levels from adult bone and teeth samples with comparisons

| Skeletal fluoride | Age | Sex | Sample source | % dry weight |
|-----------------------------------|-----------------|--------|---------------|--------------------------|
| Bahrain | | | | |
| BS40 | Adult 40+ | Male | Femur | 1.000 ¹ |
| 70A/13 | Adult femur | ? | Midsection | 0.000 |
| | | | Outer surface | 0.000 |
| 81/38 | Adult femur | ? | Midsection | 0.210 |
| S5/38 | Adult 45+ femur | Female | Midsection | 0.210 |
| | | | Outer surface | 0.280 |
| 70a/13 | | | Soil | 0.000 |
| S5/38 | | | | 0.000 |
| Comparative samples, fluoride ppm | | | | |
| <1 ppm | Adult | ? | Iliac crest | 0.019–0.073 ² |
| 0.2 ppm | | | Bone | 0.053 ³ |
| 1.0 ppm | | | Bone | 0.138 ³ |
| 2.6 ppm | | | Bone | 0.267 ³ |
| 4.0 ppm | | | Bone | 0.413 ³ |
| Dental fluoride | Age | Sex | Surface ppm F | Inner ppm F |
| Bahrain | | | | |
| R I1 B | Adult | ? | 2,100–2,500 | 200 |
| R I2 B | Adult | ? | 1,500–2,000 | 100 |
| R I2 W | Adult | ? | 1,000–4,000 | 200 |
| LM 2 W | Adult | ? | 3,000–4,000 | 200–400 |
| Comparative samples ⁴ | | | | |
| Low (<1 ppm F) | Adult | Adult | <1,000 | 100 |
| 1 ppm F | Adult | Adult | 1,000–1,500 | 100–200 |
| Severe fluorosis | Adult | Adult | 6,000 | 500 |

¹ Frohlich et al. (1989).² Zipkin et al. (1958).³ McClure et al. (1958).⁴ New Zealand Dental Research Unit.

F, fluoride

phytosis. The lesions consisted of small osteophytic outgrowths around the costal joints and along the linea aspera of the femur. None of the osteophytes was longer than 3 mm. Neither of the remaining two individuals (70A/13 and 81/14) had any evidence of excessive ossification.

Soil samples were matched for two of the samples. Neither sample contained any detectable fluoride which could have been a potential source of contamination (Table 4). As a further check of diagenetic change in these two individuals, samples were taken from both the outer surface of the cortex and a midsection of the femur. In S5/38 there was a decline in the fluoride level within the same individual, suggesting some movement of fluoride through the bone. However, in 70A/13 there was no detectable fluoride in either sample, suggesting that while fluoride was mobile through the bones, there had been no uptake of fluoride from the surrounding soil or from possible groundwater.

Normal fluoride values in bone range from 0.019–0.073% (McClure et al., 1958; Zipkin et al., 1958). The fluoride levels detected in the mid-section of 81/14 and S5/38 were three times greater and comparable with fluoride water levels of between 1.0–2.6 ppm in a temperate environment (Table 4) (McClure et al., 1958). The levels were lower than those detected in the severely affected Bronze Age individual, BS40 (Table 4) (Frohlich et al., 1989).

Chemical analysis was also conducted on four permanent teeth and compared to New Zealand data collected by the New Zealand Dental Research Unit. The four teeth selected all had some evidence of brown staining and opacity, but only one (LM2 W) had any sign of surface pitting. Scanning by electron microprobe demonstrated that fluoride had been mobile through the cementum and dentine but with little diffusion through the enamel, and the ratio of surface to inner fluoride levels was within the same range as modern teeth (Table 4) (Richards et al.,

1989). Three of the teeth demonstrated elevated fluoride levels. The inner fluoride levels of RI1 B, RI2 W, and LM2 W were comparable to dental fluoride levels observed in the temperate climate of New Zealand at water levels of 1 ppm. The tooth with pitting, LM2 W, had an inner fluoride level that ranged between expected values at 1 ppm water levels and areas of severe fluorosis.

DISCUSSION

Fluoride levels In Bahrain

The chemical analysis points to high but variable levels of fluoride intake in this population. This is not, however, clear evidence that the skeletal changes outlined above were due to skeletal fluorosis. Fluoride is subject to diagenetic change in bone, and the mobility of fluoride in the bone was demonstrated in the bone samples by the difference between the outer and midsection analyses (Table 4), which means that absolute values need to be treated with caution.

A further difficulty is that, while dental changes due to fluorosis are well-defined (Moller, 1982) and present in this sample, there is no definite association within individuals between the presence of dental and skeletal changes. The reason for this is twofold. Firstly, dental fluorosis is observable at lower fluoride levels than skeletal fluorosis, and there is no predictive relationship between the two conditions (Richards et al., 1989). Secondly, in this population extensive antemortem tooth loss among old adults makes it impossible to associate extensive osteophytic growth with dental lesions.

Apart from the chemical analysis, the presence of dental fluorosis also points to the presence of high levels of fluoride in the Bahrain samples. Cases of dental fluorosis have been recorded on the island (Barnes, 1981), while modern cases of skeletal fluorosis have also been described from nearby Qatar (Azar et al., 1961), coastal Saudi Arabia (Walters, 1954), Sharjah, and Abu Dhabi (FitzGerald-Finch, 1981), reflecting locally high levels of naturally occurring fluoride.

Water samples from a series of wells on the island confirm this. A variety of tests have been made upon spring water in Bah-

rain, resulting in values between 0.5–1.5 ppm (Matter, 1985; MUSAIGER and KHUNJI, 1990). The optimum fluoride level for retarding dental decay without adverse signs for Bahrain has been calculated at 0.5 ppm. As Matter (1985, p. 6) states, "Irrespective of which set of values are taken the overall indications are of high fluoride content in the ground water."

The variability in water levels between locations tends to be due to local variation in the substrata plus the depth of water and degree of sedimentation. It is not possible to use contemporary data to directly predict fluoride levels in the past, since differences in average temperatures, the amount of rain, and the water levels of the aquifers could cause some variation in fluoride levels. However, significant variations in the level of fluoride in underground water would not be expected over this period unless massive clearance and erosion had caused substantial leaching of fluoride from surface soil. There is no evidence on Bahrain for such massive clearance; nor do the soil samples from the burials indicate high levels of fluoride. In any case, the consequences of such erosion would be expected to result in an increased level of fluoride in the present and not explain the past frequency of fluorotic lesions.

Table 5 lists comparative percentages of skeletal and dental fluorosis with the comparable water levels in a number of different places. There is wide variation in the percentage of people affected in areas of similar water levels. The levels of dental fluorosis observed among historical groups in Bahrain are comparable with levels seen at fluoride contents of between 1–2 ppm (confirmed by the chemical analysis). The levels of skeletal fluorosis are less clear. Between 1–2.5 ppm, the percentage of individuals with skeletal fluorosis varies from 0–40.4% of the population. In the Bahrain sample, 12.7% of adults had moderate-severe enthesophytes, and 3.6% joint fusion. While some authors claim that severe fluorosis does not occur below 4 ppm (McClure et al., 1958; Kaminsky et al., 1990), others have proved the presence of severe skeletal fluorosis at water levels of 1.35–1.5 ppm, given predisposing factors (Pinet and Pinet, 1968). The

TABLE 5. Levels of fluoride in water compared to the incidence of fluorosis

| Area | F (ppm) | % fluorotic | % severe | Source |
|---------------------------|---------|-------------|------------------|------------------------|
| Dental fluorosis | | | | |
| Mexico | <0.7 | 69.0 | ND | Grimaldo et al. (1995) |
| | >2.0 | 98.0 | | |
| Southern India | 0.4 | 12.0 | ND | Nanda et al. (1974) |
| | 0.8 | 24.0 | | |
| Punjab | 0.9 | 45.0 | ND | Jolly et al. (1968) |
| | 1.4 | 13.8 | | |
| | 2.4 | 60.2 | | |
| | 3.0 | 31.2-47.6 | | |
| | 3.3 | 10.0-52.5 | | |
| | 3.6 | 49.4 | | |
| | 5.0 | 56.6 | | |
| | 8.5 | 55.5 | | |
| | 9.7 | 70.7 | | |
| Skeletal fluorosis | | | | |
| Sahara | <1.5 | 0.0 | | Pinet and Pinet (1968) |
| | 1.5-4.0 | 30.0 | | |
| Punjab | 0.3-1.4 | 30.0 | 3.6 ¹ | Jolly et al. (1973) |
| | 1.4 | ? | 2.4 | Jolly et al. (1969) |
| | 2.3 | 40.0 | 23.0 | |
| | 3.0-3.6 | 19.6-33.1 | ND | |
| | 5.0 | 60.0 | ND | |
| | 8.5-9.7 | 58.9-80.7 | 10.0 | |

¹ Based on radiological evidence.

percentage of affected individuals in the Bahrain sample may be what it is because moderate-severe enthesopathy was caused by more than just skeletal fluorosis in this population and/or because several of the predisposing factors for fluorosis occurred.

Part of the disparity can be explained by the nature of the Bahrain sample, which is comparable to an autopsy population rather than a living population. Since chronic skeletal fluorosis is a severe disease, sufferers may have a shortened life expectancy. This may explain the high proportion of severe cases compared to all cases in the group. It still fails to explain, however, why there are any crippling cases at all, given that the modern water levels are less than 1.5 ppm, unless predisposing factors did occur, or else not all enthesophytes were due to fluorosis. It is therefore necessary to examine possible causes of these lesions and determine whether skeletal fluorosis was the cause of the skeletal changes observed in this population.

Differential diagnosis

Diagnosis of these lesions must obviously be based upon a consideration of those ortho-

pedic conditions accompanied by a progressive and generalized increase in bone production, ossification of tendons and ligaments, and joint, especially spinal, ankylosis. Four possible causes of these conditions need to be considered along with skeletal fluorosis: osteoarthritis and vertebral osteophytosis, Paget's disease, diffuse idiopathic skeletal hyperostosis (DISH), and ankylosing spondylitis (Bullough and Vigorta, 1984).

Severe vertebral osteophytosis is marked by the development of beak-like osteophytes which project laterally from the vertebral body. Ankylosis, however, tends to be rare and often affects vertebral bodies in isolation. Osteophytosis is generally not associated with generalized ossification of tendons and ligaments. Osteoarthritis similarly tends to affect joints in isolation rather than the whole skeleton, and very rarely results in ankylosis (Bullough and Vigorta, 1984; Rogers and Waldron, 1995).

The later stages of Paget's disease may result in an increase in the radiodensity of bone and coarsening of trabeculae. However, this thickening is localized, often affecting only the outer borders of the vertebral body and resulting in a "picture frame" appearance (Bullough and Vigorta, 1984). In addition, the disease is often limited to the involvement of one or two bones rather than the entire skeleton, and does not involve extensive calcification of tendons and ligaments (Ortner and Putschar, 1981).

In contrast, ankylosing spondylitis primarily affects men in late adolescence/early adulthood (Riley et al., 1971). The spine gradually fuses into a block, beginning in the lumbar region. The vertebral bodies are thickened along the anterior aspect, and thin, vertically directed syndesmophytes unite contiguous vertebral bodies. Ultimately there is exaggerated kyphosis and obliteration of the intervertebral discs, so that the spine moves as a single unit. Ankylosis, however, often initially occurs in the sacroiliac joint and only later in the disc (Bullough and Vigorta, 1984). Characteristically the joint surfaces show signs of erosion. In addition, the vertebral bodies have a "squared" appearance, and osteoporosis is common. In clinical samples, about 20% of cases have peripheral joint involvement,

TABLE 6. Diagnostic features of possible causes compared to the specimens from Bahrain¹

| | Diffuse idiopathic skeletal hyperostosis | Ankylosing spondylitis | Fluorosis | Bahrain |
|------------------------------------|--|------------------------|--|------------------------|
| Age | >40 years old | ca. 20 years old | Older adults (prolonged habitation except in extremely high F areas) | >40 years old |
| Sex | M > F | M > F | M > F | M > F |
| Vertebral ankylosis | Thoracic | Late total | Lumbar first, later total | Lumbar, then total |
| Vertebral bridge | Thick osteophytes | Thin syndesmophytes | Thick osteophytes | Thick osteophytes |
| Lateral Squaring | Thoracic right > left | Central | Central | Central |
| Costovertebral/costosternal joints | Absent | Present | Absent | Absent |
| Bone | Ligament calcification | Arthritic changes | Ligament calcification | Ligament calcification |
| Peripheral joints | Normal | Osteoporotic | Osteosclerotic | Osteoclerotic |
| Dental mottling | Mainly lower | Primarily lower | Lower and upper | All |
| | Absent | Absent | Present | Present |

¹ Based on Jolly et al. (1969); Riley et al. (1971); Vernon-Roberts et al. (1974); Manchester (1982); Rogers and Waldron (1995).

predominantly in the lower limbs, including the metatarsophalangeal joints (Riley et al., 1971; Manchester, 1982). The changes tend to be arthritic in nature, with destruction of the joint surfaces.

DISH, or Forrester's disease, occurs primarily in older individuals, especially men (Rogers, 1982). The condition is diagnosed by the presence of thick bridging osteophytes, especially along the right anterolateral aspect of the thoracic spine. This may result in the ankylosis of several contiguous vertebral bodies (Vernon-Roberts et al., 1974). While the cervical and lumbar spine may be affected, the condition begins in the thoracic area with the calcification and ossification of the paraspinal ligaments. The posterior longitudinal ligaments may become ossified, and there is sometimes ankylosis of the apophyseal joints (El Garf and Khater, 1984). In general, the intervertebral disc space is preserved without marked narrowing (Vernon-Roberts et al., 1974; but see Harris et al., 1974). There may be involvement of other joints apart from the spine. The most commonly affected areas are the pelvis, upper femur, heel, and knee (Utsinger, 1985). On the pelvis, "whiskering" along the ilia is prevalent, and there tends to be para-articular osteophytosis, with calcification of ligaments such as the sacrospinous, calcaneal, and patellar ligaments. In a large sample (El Garf and Khater, 1984), skeletal findings were restricted to the spine and lower extremities. The condition rarely encompasses osteoporosis, and costochron-

dral ossification is similarly rare (Manchester, 1982). The prevalence of the disease in an autopsy population was between 6–12% of all individuals (Rogers, 1982). In this same series, 65% were male and 88% were more than 50 years of age (Rogers, 1982).

Comparison with the Bahrain lesions

Each of these diseases has similarities to the condition described at DS3. However, the Bahrain material does not suggest either osteoarthritis or Paget's disease, because of the presence of extensive ossification of tendons and ligaments, and multiple joint ankylosis. Table 6 lists the chief diagnostic features of the remaining conditions as compared to the Bahrain material.

Ankylosing spondylitis (AS) is unlikely, given the age distribution of changes in the Bahrain population. While males were more frequently affected than females in the skeletal sample, the affected individuals were much older than the age group affected by AS. In addition, vertebral bridging in AS is by thin syndesmophytes rather than the thick osteophytes observed in the Bahrain material. Osteophytes in this condition are accompanied by joint erosion, also not observed in the DS3 sample.

Apart from fluorosis, the symptoms of DISH are most similar to the lesions observed in the Bahrain population. Diagnostic criteria for DISH were described by Cruzeby (1990). The age distribution of DISH is similar to that observed in Bahrain, as are some of the other signs, such as thick osteo-

phytes on the vertebrae. There are, however, significant differences.

Fusion of vertebrae in DISH is generally along the anterolateral aspect of the body and often unilateral to the right side (Resnick and Niwayama, 1976). In contrast, fusion in the Bahrain samples occurred in the central area of the body and had no lateral preference. Sometimes in DISH the osteophytes will fuse; however, Crubezy (1990) noted that in most studies, the osteophytes have separate growths with facets between the upper and lower osteophytes. In the Bahrain material the osteophytes did not form well-defined margins, and fusion was complete. Vertebral ankylosis in DISH does not affect the intervertebral disc space, but among fused vertebrae from Bahrain there was marked narrowing of this space (Fig. 5).

There are also significant extravertebral differences. While enthesophytes did occur on the patella, calcaneus, and olecranon in the Bahrain sample, they were not restricted to these sites. Osteophytic growth was much more widespread and affected the interosseous membranes. In addition, costchondral ossification is rare in DISH (Manchester, 1982), as is ankylosis of the apophyseal joints (El Garf and Khater, 1984), yet these were frequent signs among the Bahrain material.

The closest correspondence with the lesions observed in Bahrain is with skeletal fluorosis. The epidemiological picture is consistent with a disease affecting older individuals, primarily men. Unlike DISH, vertebral ankylosis begins in the lumbar region and has no lateral preference in skeletal fluorosis and in the Bahrain material. The intervertebral space in fluorosis is narrowed, and this was observed in the Bahrain material. All joints subject to wear and tear were affected in the sample consistent with fluorosis rather than DISH. Finally, fluorosis results in osteosclerosis, with a thickened cortex—a finding observed in the Bahrain material (Fig. 5), while changes in bone density do not occur in DISH except for occasional osteoporosis (Manchester, 1982).

As Crubezy (1990) emphasized, however, diagnosis must rely upon a range of indicators, and isolating a single cause on fragmentary material may be impossible.

Distinguishing between DISH and skeletal fluorosis

In diffuse idiopathic skeletal hyperostosis, Utsinger (1985) suggests diagnosis be based upon the following criteria:

1. Continuous ossification along the anterolateral aspect of at least four contiguous bodies, primarily in the thoraco-lumbar spine (definite DISH);
2. Continuous ossification along the anterolateral aspect of at least two contiguous vertebral bodies (possible DISH); and
3. symmetrical and peripheral enthesopathy of the posterior heel, superior patella or olecranon, with the new bone having a well-defined cortical margin in the absence of inflammatory joint disease (possible DISH).

In areas with high levels of fluoride, the first and second criteria of Utsinger (1985) will not distinguish between skeletal fluorosis and DISH in a skeletal sample, although unilateral fusion is indicative of DISH rather than skeletal fluorosis (Vernon-Roberts et al., 1974). Additional criteria such as bone density, width of the intervertebral space, involvement of the apophyseal joints, completeness of fusion, and the extent of extravertebral enthesophytes need to be taken into account. Definite diagnosis between the two conditions and other enthesopathies depends upon having more than isolated skeletal elements.

In the Bahrain material, individuals with severe enthesopathy, accompanied by sclerosis and joint narrowing, most probably suffered from skeletal fluorosis. The possible confusion between DISH and fluorosis, however, means that the percentage of individuals with fluorosis is not necessarily equivalent to the percentage of individuals with moderate-severe enthesopathy, since this may incorporate some individuals with DISH, particularly moderate cases. Even so, given modern levels of fluoride on the island, it would appear that there were crippling cases of skeletal fluorosis on the island. This raises the questions of why this should be so, and of what predisposing factors may have been present.

Predisposing factors to skeletal fluorosis

Fluorosis is categorized into three stages in radiographic studies (Jolly et al., 1969; based on Roholm, 1937):

1. Blurring and coarsening of trabeculae;
2. Merging of trabeculae, narrowing of the medullary cavities, early ossification of ligaments;
3. Marbled bone, irregular periosteal thickening, and more extensive ossification (based on Roholm, 1937).

These can be compared to the three stages used for recording the degree of lesions amongst the Bahrain skeletons; stage 3 of Roholm (1937) of crippling fluorosis can be seen as roughly equivalent to the stage 3 of skeletal recording. It was initially claimed that crippling fluorosis required water levels of more than 10 ppm before it occurred (Jolly et al., 1969). More studies, however, have demonstrated that in many populations, crippling occurs above 3 ppm, and can occur at water levels of 1.35–1.5 ppm (Haikel et al., 1986; Pinet and Pinet, 1968), given the presence of predisposing factors.

Temperature is a major factor in fluorosis. In hot, dry climates, water intake is substantially greater, so that the same fluoride level in water will promote more fluorosis in a hot climate than in a temperate climate (Galagan and Lamson, 1953; Zietsman, 1991). At the same time, temperature affects evaporation rates: the greater the evaporation of water, the more concentrated fluoride becomes. Standing water in jars or pots is particularly vulnerable. High levels of fluoride-rich sediment in water can also result in a higher fluoride intake (Nanda et al., 1974).

The chemical constituents of water also have an effect on the physiological uptake of fluoride. Calcium and magnesium in water tend to inhibit fluoride ingestion, while high sodium levels and alkalinity promote fluoride ingestion (Pinet and Pinet, 1968). Similarly, a low dietary intake of calcium and phosphorus is implicated in elevated levels of skeletal fluorosis (Mithal et al., 1993). General nutritional status also plays a role, since malnourished individuals appear to be

more prone to develop dental and skeletal fluorosis (Massler and Schour, 1952).

Sources of fluoride other than water also play a role. Plants irrigated with water containing fluoride contain low levels of fluoride, while dust can be a major contaminant (Haikel et al., 1986). Smoke from fluorine-rich coal has also been identified as a cause of fluorosis in China (Wang and Huang, 1995). Fish may contain high levels of fluoride from sea water, as does sea salt, which is often used in cooking (Moller, 1982). One of the greatest dietary sources of fluoride, however, is tea (both leaf and brick forms), which has been implicated in several studies where higher than expected levels of skeletal fluorosis were found (Jackson and Weidman, 1958; Azar et al., 1961; Wang and Huang, 1995).

Finally, work in India has demonstrated that manual laborers are more likely to develop skeletal fluorosis than their sedentary counterparts (Pandit et al., 1940). This is probably because people working outside tend to drink more water. Moreover, it appears that the development of new fluorotic bone occurs at those sites most subjected to strain and minor trauma (Jolly et al., 1969; Wang et al., 1994). These factors may all predispose certain communities towards fluorosis.

On Bahrain itself, it can be hypothesized that some of these factors applied. Firstly high temperatures, particularly in summer, plus the shallowness of the subsurface water, would all increase the fluoride level in water. Any storage of water in pots, which presumably occurred in the case of household water, would have caused a concentration of fluoride. Since the level of sodium in the water tends to be high on the island, this would also serve to increase fluoride intake (Musaiger and Khunji, 1990).

In addition, sea water in the Arabian Gulf contains between 3.36–8.72 ppm, resulting in a high fluoride content in fish (Azar et al., 1961). Since fish are traditionally a major source of protein on the island, this would also be a reason for elevated levels of skeletal fluorosis. With regard to nutritional adequacy it is difficult to draw any conclusions, but historically, diets in the Middle East region tend to be low in calcium which

would predispose the population, particularly those doing heavy agricultural labor, to fluorosis (Walters, 1954; El Tannir, 1959).

Finally, this population came from an agricultural village where many men were presumably involved in manual labor (Littleton, 1998). This is precisely the group most likely to develop skeletal fluorosis, because of their greater water intake and harder physical labour (Jolly et al., 1969).

Therefore, despite only moderate levels of fluoride in the groundwater, the number of predisposing factors present on Bahrain means that skeletal fluorosis was a health problem for this community in the past. The levels of fluorosis observed are equivalent to those found in areas of low chronic endemicity in India and the Sahara (Teotia and Teotia, 1984; Pinet and Pinet, 1968). It can be expected that, as in similar areas today (Jolly et al., 1973; Haimanot, 1990), the presence of skeletal fluorosis would have had a social impact.

Possible social impact of skeletal fluorosis

In skeletal fluorosis there is only a loose link between the degree of skeletal lesions and disability, except in extreme cases (Chen-Yueng et al., 1983). There is, however, a general progression in the clinical course of fluorosis. Early signs are vague pains and arthralgia. This generally progresses to backache, pain in the spine, and signs of stiffness and rigidity as well as constipation. With increasing calcification of tendons and ligaments there is a limitation of joint movement and inability to close the fist. The final stages of the disease are associated with stage 3 and include difficulty in walking, with a generalized attitude of flexion and ankylosis until the spine and chest become fixed and the sufferer is crippled (Teotia and Teotia, 1988). In rare cases, neurological complications occur due to compression of the spinal cords and radiomyelopathy (Misra et al., 1988; Naidu et al., 1988).

Faccini and Teotia (1974) described 10 patients with typical signs of moderate to severe skeletal fluorosis. While three had flexion deformities of the spine, none were completely immobilized despite extensive ossification. In addition, Faccini and Teotia

(1974, p. 47) stated that "all were able to perform, at least, domestic work." This disparity between the physical signs of fluorosis and its effects is important to remember when gauging what effect fluorosis has upon a population.

A second factor to be accounted for is that the degree of disability experienced is often related to physical strain through life (Pandit et al., 1940). It appears that the bones most subject to stress are most likely to develop lesions. Thus in India, male agricultural workers tend to develop exostoses in the lumbar region and lower limbs, while among females, changes are most common in the wrist, shoulder, and neck (Jolly et al., 1969).

Applying these two factors to the skeletal population from Bahrain, the effects of fluorosis would not be apparent except among those over 40 years of age and, in particular, males. In the DS3 group, 2.6% of adults showed evidence of joint ankylosis. These were all men over 50 years of age at the time of death. There were no signs of quadriplegia, as was evident in the Bronze Age skeleton recorded by Frohlich et al. (1989). Nevertheless, in terms of heavy labor it is unlikely that, given the extensive vertebral ossification, these men would have been full participants in the workforce, though there may have been little limitation in their performance of lighter tasks. In the younger age groups, apart from increasing stiffness, there may have been little impact of this disease.

The importance of skeletal fluorosis is seen in that it may have meant that older adults were not as economically independent as younger members of the society. At least some would have had difficulty in moving freely, making their performance of heavy labor difficult, and in severe cases placing a burden upon younger members. It does, however, appear that this most extreme instance only rarely arose, since less than 10% of the population survived beyond 50 years. Nevertheless, in a population with a high level of dependents, skeletal fluorosis in its severe form would have been an additional public health problem.

CONCLUSIONS

In areas where naturally occurring levels of fluoride are high, skeletal fluorosis needs to be considered as a possible cause of hyperostotic conditions in skeletal samples. Distinguishing between fluorosis and DISH may be difficult in fragmentary and less severe cases. However, the additional criteria of joint space narrowing, osteosclerosis, lack of laterality in vertebral ankylosis, and upper and lower peripheral joint involvement will aid in distinguishing the two conditions.

The prevalence of skeletal fluorosis in skeletal samples will not, however, be directly predictable from water levels of fluoride in the past. In Bahrain it appears probable that predisposing factors may have operated in the past, and these also need to be considered in any identification of the disease. Yet in many areas of the world today, skeletal fluorosis is a major public health issue (Wang and Huang, 1995), and probably was in the past.

ACKNOWLEDGMENTS

Access to skeletal material and help during recording was provided by Shaika Naila Al-Khalifa and the staff of the Bahrain National Museum. I greatly appreciate their assistance, as well as that of my supervisors Bruno Frohlich and Colin Groves. Dr. Grace Suckling generously undertook analysis of the dental samples. Lissant Bolton, Peter Dowling, and three anonymous reviewers provided constructive comments on this paper; I thank them for their efforts, and claim responsibility for any remaining errors.

LITERATURE CITED

- Angel JL. 1971. The people of Lerna. Washington, DC: Smithsonian Press. p 159.
- Azar H, Nucho C, Bayyuk S, Bayyuk H. 1961. Skeletal sclerosis due to chronic fluoride intoxication. *Ann Intern Med* 55:193-200.
- Barnes D. 1981. Oral health situation analysis, Bahrain. Report to the World Health Organisation, Bahrain. p 15.
- Bass W. 1981. Human osteology. MO: Missouri Archaeological Society. p 327.
- Brothwell D. 1981. Digging up bones. London: British Museum of Natural History. p 208.
- Bullough P, Vigorta V. 1984. Atlas of orthopaedic pathology. New York: Gower Medical Publishing. p 259.
- Chen-Yueng M, Wong R, Tan F, Enarson D, Schulzar M, Knickerbocker J, Subarao K, Grzybowski S. 1983. Epidemiologic health study of workers in an aluminum smelter in Kitimat, B.C. II. Effects on musculoskeletal and other systems. *Arch Environ Health* 38:34-40.
- Chibole O. 1987. Epidemiology of dental fluorosis in Kenya. *J R Soc Health* 107:242-243.
- Christie D. 1980. The spectrum of radiographic bone changes in children with fluorosis. *Radiology* 136:85-90.
- Crubezy E. 1990. Diffuse idiopathic skeletal hyperostosis: diagnosis and importance in paleopathology. *J Paleopathol* 3:107-118.
- Dean H. 1934. Classification of mottled enamel diagnosis. *J Am Dent Assoc* 21:1421-1426.
- El Garf A, Khater R. 1984. Diffuse idiopathic skeletal hyperostosis (DISH). A clinicoradiological study of the disease pattern in Middle Eastern populations. *J Rheumatol* 11:804-807.
- El Tannir M. 1959. Mottling of the enamel in Mecca and the Arabian Peninsula—"a survey and research study carried out in Saudi Arabia. *Am J Public Health* 49:45-52.
- Faccini J, Teotia S. 1974. Histopathological assessment of endemic skeletal fluorosis. *Calcif Tissue Res* 16:45-57.
- FitzGerald-Finch O. 1981. Radiology in the Middle East: a review of ten thousand cases. *J Trop Med Hyg* 84:37-40.
- Frohlich B, Ortner D, Al Khalifa H. 1989. Human disease in the ancient Middle East. *Dilmun* 14:61-73.
- Galagan D, Lamson G. 1953. Climate and endemic dental fluorosis. *Public Health Rep* 68:497-508.
- Grimaldo M, Borja-Aburto V, Ramirez A, Ponce M, Rosos M, Dios-Barrigo F. 1995. Endemic fluorosis in San Luis Potosi, Mexico. I. Identification of risk factors associated with human exposure to fluoride. *Environ Res* 68:25-30.
- Haikel Y, Voegel J, Frank R. 1986. Fluoride content of water, dust, soils and cereals in the endemic fluorosis area of Kouribga (Morocco). *Arch Oral Biol* 31:279-286.
- Haimanot R. 1990. Neurological complications of endemic skeletal fluorosis with special emphasis on radiculo-myelopathy. *Paraplegia* 28:244-251.
- Harris J, Carter A, Glick E, Storey G. 1974. Ankylosing hyperostosis 1. Clinical and radiological features. *Ann Rheum Dis* 33: 210-215.
- Jackson D, Weidman S. 1958. Fluorine in human bone related to age and the water supply of different regions. *J Pathol Bacteriol* 86:451-459.
- Jolly S, Singh B, Mathur O, Malhorta K. 1968. Epidemiological, clinical and biochemical study of endemic dental fluorosis in the Punjab. *Br Med J [Clin Res]* 4:427-429.
- Jolly S, Singh B, Mathur O. 1969. Endemic fluorosis in Punjab (India). *Am J Med* 47:553-563.
- Jolly S, Prasad S, Sharma R, Chandler R. 1973. Endemic fluorosis in India. *Fluoride* 6:4-18.
- Kaminsky L, Mahoney M, Leach J, Melius J, Miller M. 1990. Fluoride: benefits and risks of exposure. *Crit Rev Oral Biol Med* 1:261-281.
- Krishnamachari K. 1986. Skeletal fluorosis in humans: a review of recent progress in the understanding of the disease. *Prog Food Nutr Sci* 10:279-314.
- Larsen C. 1983. Holocene land use on the Bahrain Islands. Chicago: Chicago University Press. p 339.
- Littleton J. 1993. Articulating the past: an osteosocial analysis. Ph.D. thesis, Australian National University.
- Littleton J. 1998. Skeletons and social composition: Bahrain 300 BC-250 AD. Oxford: Archaeopress. p 154.
- Littleton J, Frohlich B. 1989. An analysis of dental pathology from historic Bahrain. *Paleorient* 15:59-75.

- Lovejoy O, Meindl R, Barton T, Mensforth R. 1985. Chronological metamorphosis of the auricular surface of the ilium: a new method for the determination of adult skeletal age at death. *Am J Phys Anthropol* 68:15-28.
- Lukacs J, Retief D, Jarrige J. 1985. Dental disease in prehistoric Baluchistan. *Natl Geogr Res* 1:184-197.
- Manchester K. 1982. An ossifying diathesis of 1st century AD date. *Proc Eur Meet Paleopathol Assoc* 4:267-281.
- Mariano-Menez M, Wakley G, Farley S, Baylink D. 1990. Fluoride metabolism and the osteoporotic patient. In: Simmons D, editor. *Nutrition and bone development*. Oxford: Oxford University Press. p 295-301.
- Massler M, Schour I. 1952. Relation of endemic dental fluorosis to malnutrition. *J Am Dent Assoc* 44:156-165.
- Matter A. 1985. Investigations on fluorides in Bahrain. Marama: Environmental Protection Agency, Bahrain. 10 p.
- McClure F, McCann H, Leone N. 1958. Excessive fluoride in water and bone chemistry. *Public Health Rep* 73:741-746.
- Meindl R, Lovejoy C. 1985. Ectocranial suture closure: a revised method for the determination of skeletal age at death based on the lateral-anterior sutures. *Am J Phys Anthropol* 44:507-512.
- Meindl R, Lovejoy C, Mensforth R, Walker R. 1985. A revised method of age determination using the os pubis, with a review and tests of accuracy of other current methods of pubic symphyseal aging. *Am J Phys Anthropol* 68:29-45.
- Misra U, Husain M, Newton G, Nag D, Ray P. 1988. Endemic fluorosis presenting as cervical cord depression. *Arch Environ Health* 43:18-21.
- Mithal A, Trivedi N, Gupta S, et al. 1993. Radiological spectrum of endemic fluorosis: relationship with calcium intake. *Skeletal Radiol* 22:257-261.
- Moller I. 1982. Fluorides and dental fluorosis. *Int Dent J* 32:135-147.
- Moller PF, Gudjonsson S. 1967. Massive fluorosis of bones and ligaments. *Clin Orthop* 55:5-15.
- Moudgil A, Srivastava R, Vasudev A, Bagga A, Gupta A. 1986. Fluorosis with crippling skeletal deformities. *Indian Pediatr* 23:767-773.
- Musaiger A, Khunji Z. 1990. Chemical quality of drinking water in Bahrain. *J R Soc Health* 3:104-105.
- Mwainiki D, Courtney J, Gaylor J. 1994. Endemic fluorosis: an analysis of needs and possibilities based on case studies in Kenya. *Soc Sci Med* 39:807-813.
- Naidu M, Dinakar I, Rao K, et al. 1988. Intraosseous schwannoma of the cervical spine associated with skeletal fluorosis. *Clin Neurol Neurosurg* 90:257-260.
- Nanda R, Zipkin I, Doyle J, Horowitz H. 1974. Factors affecting the prevalence of dental fluorosis in Lucknow, India. *Arch Oral Biol* 19:781-792.
- Ortner D, Putschar W. 1981. Identification of pathological conditions in human skeletal remains. Washington, DC: Smithsonian Press. 488 p.
- Pandit C, Raghavachari T, Rao D, Krisnamorli V. 1940. Endemic fluorosis in South India. *Indian J Med Res* 28:533-558.
- Phenice T. 1969. A newly developed visual method of sexing the os pubis. *Am J Phys Anthropol* 30:297-302.
- Pinet A, Pinet F. 1968. Endemic skeletal fluorosis in the Sahara. *Fluoride* 1:86-93.
- Powell ML. 1988. Health and status in prehistory. Washington, DC: Smithsonian Press. 242 p.
- Resnick D, Niwayama G. 1976. Radiographic and pathologic features of spinal involvement in diffuse idiopathic skeletal hyperostosis (DISH). *Radiology* 119:559-568.
- Richards A, Fejerskov O, Baelum V. 1989. Enamel fluoride in relation to severity of human dental fluorosis. *Adv Dent Res* 3:148-153.
- Riley M, Ansell B, Bywaters E. 1971. Radiological manifestations of ankylosing spondylitis according to age at onset. *Ann Rheum Dis* 30:138-145.
- Rogers J. 1982. Diffuse idiopathic skeletal hyperostosis in ancient populations. *Proc Eur Meet Paleopathol Assoc* 4:94-105.
- Rogers J, Waldron T. 1995. A field guide to joint disease in archaeology. Chichester: John Wiley and Sons. 138 p.
- Rogers J, Watt I, Dieppe P. 1987. Palaeopathology of spinal osteophytosis, vertebral ankylosis, ankylosing spondylitis, and vertebral hyperostosis. *Ann Rheum Dis* 44:113-120.
- Roholm K. 1937. Fluorine intoxication. London: Lewis. 213 p.
- Salles J-F. 1987. The Arab-Persian Gulf under the Seleucids. In: Kuhurt A, Sherwin-White S, editors. *Hellenism in the East*. London: Duckworth. p 75-184.
- Suckling G, Cuttress T. 1992. Proton microprobe determination of profiles of fluoride levels in the enamel and dentine of human teeth. *J Paleopathol Monogr Publ* 2:391-400.
- Szpunar C, Lambert J, Buikstra J. 1978. Analysis of excavated bone by atomic absorption. *Am J Phys Anthropol* 48:199-202.
- Teotia S, Teotia M. 1984. Endemic fluorosis in India: a challenging national health problem. *J Assoc Physicians India* 32:347-352.
- Teotia S, Teotia M. 1988. Endemic skeletal fluorosis: clinical and radiological variants. *Fluoride* 21:39-44.
- Thylstrup A, Fejerskov O. 1978. Clinical appearance of dental fluorosis in permanent teeth in relation to histologic changes. *Community Dent Oral Epidemiol* 6:315-328.
- Torino M, Rognini M, Fornaciari G. 1995. Dental fluorosis in ancient Herculaneum [letter]. *Lancet* 345:1306.
- Utsinger P. 1985. Diffuse idiopathic skeletal hyperostosis. *Clin Rheumatol Dis* 2:325-351.
- Vernon-Roberts B, Pirie C, Trentwith V. 1974. Pathology of the dorsal spine in ankylosing hyperostosis. *Ann Rheum Dis* 33:281-288.
- Walters J. 1954. Uncommon endemic diseases of the Persian Gulf area. *Trans R Soc Trop Med Hyg* 48:385-394.
- Wang L, Huang J. 1995. Outline of control practice of endemic fluorosis in China. *Soc Sci Med* 41:1191-1195.
- Wang Y, Yin Y, Gilula L, Wilson A. 1994. Endemic fluorosis of the skeleton: radiographic features in 127 patients. *Am J Radiol* 162:93-98.
- Zietsman S. 1991. Spatial variation of fluorosis and fluoride content of water in an endemic area in Bophuthawswana. *J Dent Assoc S Afr* 46:11-15.
- Zipkin I, McClure F, Leone N, Lee W. 1958. Fluoride deposition in human bones after prolonged ingestion of fluoride in drinking water. *Public Health Rep* 73:732-740.